

Prognostic Impact of CD3 Tumor Infiltrating Lymphocytes in Triple-negative Breast Cancer

ANKITA SINGH RATHORE*, MADHU MATI GOEL*, ANNU MAKKER*, SANDEEP KUMAR**, AN SRIVASTAVA†

ABSTRACT

Background: Aim of the present study was to evaluate the prognostic significance of CD3+ tumor infiltrating lymphocyte (TILs) in triple-negative breast cancer (TNBC). **Methods:** Immunohistochemistry was done with antibodies to CD3 TIL, estrogen receptors (ERs), progesterone receptor (PR) and C-erbB2 in tissue sections of 49 TNBC patients. CD3+ intratumoral and stromal TILs were counted in relation to known clinicopathological factors. **Results:** Intratumoral CD3+ TILs were significantly associated with stage ($p = 0.05$) with insignificant association with age, menopausal status, family history, grade and lymph node status. Higher counts of stromal CD3+ TILs were significantly associated with stage ($p = 0.05$), whereas grade, lymph node status, age, menopausal status and family history were insignificant with CD3+ count. The higher CD3 intratumoral and stromal counts both showed significant association with good prognosis ($p 0.05$). **Conclusion:** CD3+ TILs may serve as good prognostic marker in TNBC. The results of present study need further validation on larger sample size.

Keywords: Tumor infiltrating lymphocytes, triple-negative breast cancer

Breast cancer is one of the most frequent causes of cancer death in women worldwide¹ and is second most common cancer in females in India.² The predictable prognostic factors in breast cancer include histological grade, clinical stage, lymph node and hormone receptor status. Higher clinical staging and grading are known bad prognostic markers. Lymph node positivity also indicates bad prognosis. However, each kind of tumor has different biological behavior. Triple-negative breast cancer (TNBC) is clearly a distinct subtype of breast cancer.³ TNBC lacks the expression of estrogen receptor (ER), progesterone receptor (PR) and C-erbB2. TNBC are known to be more aggressive with worse prognosis.

Tumor infiltrating lymphocytes (TILs) have been thought to play an important role in inhibiting tumor proliferation, metastasis in tumors and may be an

independent prognostic marker.⁴⁻⁷ The infiltrating lymphocytes counts within the tumor cell have been reported to associate with good prognosis in different kind of tumors.⁸⁻¹¹

CD3 antigen is a receptor glycoprotein present on all T lymphocytes. Controversy still surrounds the prognostic role of TILs within a tumor microenvironment. While higher concentration of CD3 TIL has been shown to link with favorable outcome in oropharyngeal cancer,¹² a low CD3 count has been reported to predict a shorter disease free survival in colon and cervical cancer.^{13,14}

Role of TIL in TNBC is not well-understood. The present study was done to evaluate the density, localization and distribution of CD3 TIL in TNBC patients. The findings were correlated with known clinicopathological factors and survival.

MATERIAL AND METHODS

Patients

A total of 25 histologically proven cases of TNBC recruited from the Dept. of General Surgery, King George's Medical University, Lucknow, Uttar Pradesh, India after informed written consent and institutional ethical clearance were included in this study. Demographic details, clinical history, complete general/local examination and epidemiological risk factors including family history, clinical stage, tumor grade,

*Dept. of Pathology, King George's Medical University
Lucknow, Uttar Pradesh

**All India Institute of Medical Sciences, Bhopal, Madhya Pradesh

†Dept. of Pathology, Era's Lucknow Medical College and Hospital, Lucknow
Uttar Pradesh

Address for correspondence

Dr Ankita Singh Rathore
SRF, Dept. of Pathology
King George's Medical University
Lucknow - 226 003, Uttar Pradesh
E-mail: ankita.rathorekg@gmail.com

lymph node status, ER, PR and Cerb B2 were recorded on a detailed proforma specially designed for the study. All patients had preoperative tissue diagnosis of breast cancer either by fine-needle aspiration cytology (FNAC) and/or core biopsy of the breast. All the patients underwent surgery with axillary lymph node dissection, and none of these patients had received preoperative antitumor therapy. Detailed histopathological examination was done in the Dept. of Pathology, King George Medical University Lucknow, Uttar Pradesh.

Immunohistochemistry

Immunohistochemistry (IHC) was performed using primary antibodies to CD3+ (Novacastra, UK), ER, PR and CerbB-2 (Biogenex Laboratories, Inc, CA, US). Sections were deparaffinized in xylene followed by hydration in graded ethanols. Secondary antibody kit used was polymer detection kit (Novacastra, UK).

Formalin-fixed, paraffin-embedded tissues sections (3-4 μm thick) were taken on 3-aminopropyl triethoxysilane (APTS)-coated glass slides. Sections were immersed in antigen-retrieval solution (Citrate buffer pH 6.0) and antigen retrieval was done in the antigen-retrieval system (Biogenex Laboratories, Inc, CA, US) at 100°C for 20 minutes. The sections were then brought to room temperature. Endogenous peroxidase activity was blocked in 3% hydrogen peroxide for 5 minutes and nonspecific binding sites were blocked with protein block for 5 minutes. Sections were covered with 50 μl of individual primary antibody, kept in moist chamber and slides were incubated over night at 40°C. Slides were then washed with tris buffer saline (TBS), followed by a 30 minutes incubation with post-primary block at room temperature (RT). Sections were then washed again in TBS and incubated with secondary antibody for 30 minutes at RT. 3,3-diamino-benzidine was used as chromogen for visuation of antigen antibody complex. Sections were counterstained with hematoxylin and mounted with DPX. Section from tonsillar tissue was taken as positive control for CD3+ cells.

Microscopic Evaluation of CD3 TIL

CD3 positive TILs were counted in five randomly selected high power fields at 40X magnification and the counts were averaged. Initially, CD3 positive TILs count was recorded as: + (1-25 cells), ++ (≥ 25 cells) in the tumor and in the stroma separately. CD3 positive TIL upto 25 cells were considered as low CD3 TIL count and above 25 cells i.e. ++ were considered as high count.

The mean follow-up period was 32 months. Follow-up data were available for all patients. Details of clinical progress and survival were obtained from the hospital records. During the follow-up period, eight patients were not well (recurrence/death). The histomorphology and immunostaining patterns of intratumoral and stromal CD3 TILs are shown in Figures 1 a and b.

Statistical Analysis

Statistical software Stata 11.2 version was used for statistical analysis. The data were described as number and percentages or mean \pm SD, as applicable. Chi-square test (χ^2) was used to test the association between categorical variables. The age was compared by Mann-Whitney test because of non-normal nature of our data.

RESULTS

The clinicopathological characteristics of the patients included in this study are summarized in Table 1. The median age of study sample was 50 years (range 25-86 mean 49.16 years). Out of 25 TNBC patients, majority of the cases were postmenopausal (64%). All patients were recruited in the study were TNBC showing higher clinical stage (T3,T4) with 66%, higher histological grade (III, IV) with 52% and lymph node positivity with 60%.

The scoring of intratumoral and CD3+ TILs in relation to clinicopathological variables is shown in Table 2. CD3 positive TILs were detected in intratumoral and stromal areas of immunostained histological sections of all the TNBC. Intratumoral CD3+ TILs were significantly associated with clinical stage ($p = 0.05$). The association of intratumoral CD3 TIL was insignificant in relation to age, menopausal status, family history, histological grade and lymph node status (Table 2). Similarly, the stromal CD3 TIL was also significantly associated with clinical stage ($p = 0.05$), whereas age, menopausal status, family history, grade and lymph node status did not show significant association with CD3+ stromal TIL count (Table 2). Immunostaining of intratumoral and stromal CD3 TIL are shown in (Figs. 1 a and b).

Follow-up for disease-free survival was available for 17 patients. In our analysis, patient with higher intratumoral and stromal CD3+ T-cell infiltration showed a longer disease-free survival ($p = 0.004$) and ($p = 0.01$), respectively. Higher number of CD3+ TILs were observed to be associated with better outcome.

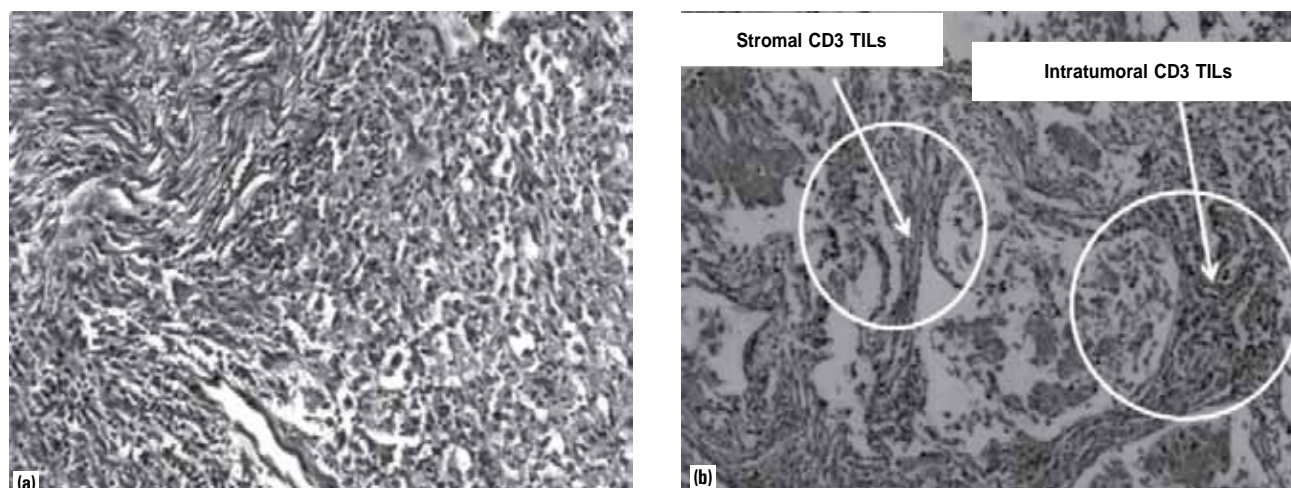


Figure 1 a and b. Show intratumoral and stromal TILs in TNBC; section showing intratumoral and stromal area of TNBC (H&E x100) (a); immunostain section showing CD3 + in intratumoral and stromal area of TNBC (H&x 100) (b).

Table 1. Clinicopathological Characteristics of the Breast Cancer Patients

| Characteristics | n = 25 (100%) |
|--------------------------|-----------------------|
| Age (years) | |
| Mean ± SD (range) | 49.16 ± 12.62 (25-86) |
| Menopausal status | |
| Premenopause | 9 (36%) |
| Postmenopause | 16 (64%) |
| Family history | |
| Yes | 2 (8%) |
| No | 23 (92%) |
| Grade | |
| I, II | 12 (48%) |
| III, IV | 13 (52%) |
| Tumor stage | |
| T1,T2 | 11 (44%) |
| T3,T4 | 14 (66%) |
| Lymph node status | |
| Positive | 15 (60%) |
| Negative | 10 (40%) |
| Survival status | |
| Well | 17 (68%) |
| Not well | 8 (32%) |

DISCUSSION

Patients with TNBC have significantly bad prognosis, compared to women with other sybtypes of breast cancer. The fundamental difference between relapse

and mortality rate of patients may be elucidated in part by different steps of metastatic spread.¹⁵ The current assumption is that TNBC metastasize to axillary lymph nodes and bone less frequently than the non TNBC subset of breast cancer, favoring a hematogenous spread.^{16,17}

In the present study, we observed significantly high intratumoral CD3+ counts in relation to tumor stage. Association of CD3+ TILs with other factors like age, menstrual status, family history, histological grade and lymph node status were not significant. High grade, stage and lymph node positivity are known poor prognostic factors in breast cancer. Similar findings have been reported for medullary carcinoma of breast by other workers.¹⁸ The presence of CD3+ TILs has been attributed to the positive outcome in several studies.^{19,20} The high counts of CD3+ TILs compared to low counts have been reported to be associated with better survival in Stage IB cervical cancer.²¹ In a recent study, the presence of intratumoral CD3+ TILs was associated with better survival in epithelial ovarian cancer.²² It is well-known that women with TNBC had significantly shorter disease free and overall survival time than other subtypes.²³ The high intratumoral and stromal TILs in our study predicted longer survival ($p = 0.004$ and $p = 0.01$), respectively), implying that higher CD3+ TILs may act as good prognostic marker in TNBC.

We used IHC for CD3+ TILs semi-quantification, which had the distinct advantage of morphologically observing the TILs in intratumoral and stromal areas. Further, the size of the histological sections taken for

Table 2. Association of Intratumoral and Stromal CD3+ Count with Clinicopathological Characteristics

| Variables | Intratumoral CD3+ count | | | Stromal CD3+ count | | |
|---------------------------|-------------------------|------------------------|---------|------------------------|------------------------|---------|
| | Low (n = 8) | High (n = 17) | p value | Low (n = 9) | High (n = 16) | p value |
| Age (years) | | | | | | |
| Mean ± SD (range) | 52.3 ± 11.7 (30-80) | 48.5 ± 13.4 (25-86) | 0.49 | 49.8 ± 14.4 (26-87) | 49.5 ± 12.2 (26-85) | 0.96 |
| Menstrual status | | | | | | |
| Premenopause | 4 (50%) | 5 (29.41%) | 0.40 | 3 (33.33%) | 6 (37.5%) | 1.00 |
| Postmenopause | 4 (50%) | 12 (70.59%) | | 6 (66.67%) | 10 (62.5%) | |
| Family history | | | | | | |
| No | 8 (100%) | 15 (88.24%) | 1.00 | 8 (88.89%) | 15 (93.75%) | 1.00 |
| Yes | 0 | 2 (11.76%) | | 1 (11.11%) | 1 (6.25%) | |
| Grade | | | | | | |
| I-II | 2 (25%) | 10 (58.82%) | 0.20 | 2 (22.22%) | 10 (62.5%) | 0.09 |
| III-IV | 6 (75%) | 7 (41.18%) | | 7 (77.78%) | 6 (37.5%) | |
| Stage | | | | | | |
| T1-T2 | 1 (12.5%) | 10 (58.82%) | 0.04 | 1 (11.11%) | 10 (62.5%) | 0.03 |
| T3-T4 | 7 (87.5%) | 7 (41.18%) | | 8 (88.89%) | 6 (37.5%) | |
| Lymph node | | | | | | |
| Negative | 2 (25%) | 8 (47.06%) | 0.40 | 3 (33.33%) | 7 (43.75%) | 0.69 |
| Positive | 6 (75%) | 9 (52.94%) | | 6 (66.67%) | 9 (56.25%) | |
| Treatment response | | | | | | |
| Well | 2 (25%) | 15 (88.24%) | 0.004 | 3 (33.33%) | 14 (87.5%) | 0.01 |
| Not well | 6 (75%) | 2 (11.76%) | | 6 (66.67%) | 2 (12.5%) | |

IHC is also significant if morphological observations are to be made separately within the tumor areas and the stromal component. We performed IHCs on larger tissue sections obtained from resected specimens, not on core biopsies. The idea in our study was to locate whether IHC with infiltrating CD3+ TILs could be used as an adjunct to all cases of TNBC. This could be useful in stratifying the patients into high-risk or low-risk category at the time of tissue diagnosis on resected specimen.

CONCLUSION

The present study proposes that detection of the density and location of CD3+ TILs in TNBC could be a good prognostic factor. A larger number of sample size need to be studied and linked with their survival.

REFERENCES

- Key TJ, Verkasalo PK, Banks E. Epidemiology of breast cancer. *Lancet Oncol* 2001;2(3):133-40.
- Ferlay J, Shin HR, Bray F, Forman D, Mathers C, Parkin DM. Estimates of worldwide burden of cancer in 2008: GLOBOCAN 2008. *Int J Cancer* 2010;127(12):2893-917.
- Dent R, Hanna WM, Trudeau M, Rawlinson E, Sun P, Narod SA. Pattern of metastatic spread in triple-negative breast cancer. *Breast Cancer Res Treat* 2009;115(2):423-8.
- Galon J, Costes A, Sanchez-Cabo F, Kirilovsky A, Mlecnik B, Lagorce-Pagès C, et al. Type, density, and location of immune cells within human colorectal tumors predict clinical outcome. *Science* 2006;313(5795):1960-4.
- Chiba T, Ohtani H, Mizoi T, Naito Y, Sato E, Nagura H, et al. Intraepithelial CD8+ T-cell-count becomes a prognostic factor after a longer follow-up period in human colorectal carcinoma: possible association with suppression of micrometastasis. *Br J Cancer* 2004;91(9):1711-7.
- Schumacher K, Haensch W, Röefzaad C, Schlag PM. Prognostic significance of activated CD8(+) T cell infiltrations within esophageal carcinomas. *Cancer Res* 2001;61(10):3932-6.
- Nakano O, Sato M, Naito Y, Suzuki K, Orikasa S, Aizawa M, et al. Proliferative activity of intratumoral CD8(+) T-lymphocytes as a prognostic factor in human renal cell

- carcinoma: clinicopathologic demonstration of antitumor immunity. *Cancer Res* 2001;61(13):5132-6.
8. Black MM, Speer FD, Opler SR. Structural representations of tumor-host relationships in mammary carcinoma; biologic and prognostic significance. *Am J Clin Pathol* 1956;26(3):250-65.
 9. Aaltomaa S, Lipponen P, Eskelinen M, Kosma VM, Marin S, Alhava E, et al. Lymphocyte infiltrates as a prognostic variable in female breast cancer. *Eur J Cancer* 1992;28A(4-5):859-64.
 10. Di Giorgio A, Mingazzini P, Sammartino P, Canavese A, Arnone P, Scarpini M. Host defense and survival in patients with lung carcinoma. *Cancer* 2000;89(10):2038-45.
 11. Clemente CG, Mihm MC Jr, Bufalino R, Zurrada S, Collini P, Cascinelli N. Prognostic value of tumor infiltrating lymphocytes in the vertical growth phase of primary cutaneous melanoma. *Cancer* 1996;77(7):1303-10.
 12. Rajjoub S, Basha SR, Einhorn E, Cohen MC, Marvel DM, Sewell DA. Prognostic significance of tumor-infiltrating lymphocytes in oropharyngeal cancer. *Ear Nose Throat J* 2007;86(8):506-11.
 13. Sinicrope FA, Rego RL, Ansell SM, Knutson KL, Foster NR, Sargent DJ. Intraepithelial effector (CD3+)/regulatory (FoxP3+) T-cell ratio predicts a clinical outcome of human colon carcinoma. *Gastroenterology* 2009;137(4):1270-9.
 14. Ancuta E, Ancuța C, Zugun-Eloae F, Iordache C, Chiriac R, Carasevici E. Predictive value of cellular immune response in cervical cancer. *Rom J Morphol Embryol* 2009;50(4):651-5.
 15. Dent R, Hanna WM, Trudeau M, Rawlinson E, Sun P, Narod SA. Time to disease recurrence in basal-type breast cancers: effects of tumor size and lymph node status. *Cancer* 2009;115(21):4917-23.
 16. Fulford LG, Reis-Filho JS, Ryder K, Jones C, Gillett CE, Hanby A, et al. Basal-like grade III invasive ductal carcinoma of the breast: patterns of metastasis and long-term survival. *Breast Cancer Res* 2007;9(1):R4.
 17. Rodríguez-Pinilla SM, Sarrió D, Honrado E, Hardisson D, Calero F, Benitez J, et al. Prognostic significance of basal-like phenotype and fascin expression in node-negative invasive breast carcinomas. *Clin Cancer Res* 2006;12(5):1533-9.
 18. Guo X, Fan Y, Lang R, Gu F, Chen L, Cui L, et al. Tumor infiltrating lymphocytes differ in invasive micropapillary carcinoma and medullary carcinoma of breast. *Mod Pathol* 2008;21(9):1101-7.
 19. Rabinowich H, Cohen R, Bruderman I, Steiner Z, Klajman A. Functional analysis of mononuclear cells infiltrating into tumors: lysis of autologous human tumor cells by cultured infiltrating lymphocytes. *Cancer Res* 1987;47(1):173-7.
 20. Topalian SL, Solomon D, Rosenberg SA. Tumor-specific cytotoxicity by lymphocytes infiltrating human melanomas. *J Immunol* 1989;142(10):3714-25.
 21. Baxevanis CN, Dedoussis GV, Papadopoulos NG, Missitzis I, Stathopoulos GP, Papamichail M. Tumor specific cytotoxicity by tumor infiltrating lymphocytes in breast cancer. *Cancer* 1994;74(4):1275-82.
 22. Zhang L, Conejo-Garcia JR, Katsaros D, Gimotty PA, Massobrio M, Regnani G, et al. Intratumoral T cells, recurrence, and survival in epithelial ovarian cancer. *N Engl J Med* 2003;348(3):203-13.
 23. Banerjee S, Reis-Filho JS, Ashley S, Steele D, Ashworth A, Lakhani SR, et al. Basal-like breast carcinomas: clinical outcome and response to chemotherapy. *J Clin Pathol* 2006;59(7):729-35.



It Even Happens in US: Doctor Gave Chemo to Patients without Cancer

Hematologist-oncologist Farid Fata, MD, in suburban Detroit, Michigan, was arrested August 6 and charged with Medicare fraud. In a criminal complaint filed in a federal district court in Detroit, prosecutors said that the 48-year-old Dr Fata ordered toxic chemotherapy for patients who did not have cancer or whose cancer was in remission.

Rather than keeping their heads down, some employees at Dr. Fata's high-profile practice challenged his actions before he was arrested, according to the government. One employed oncologist, for example, told agents from the FBI and the Dept. of Health and Human Services that he discovered that Dr Fata had ordered chemotherapy for a patient whose cancer was in remission.

This oncologist and other employees also reported that Dr Fata ordered intravenous immunoglobulin (IVIG) for patients whose antibody levels did not warrant the therapy. One nurse practitioner (NP) told federal agents that she pulled the charts for 40 patients scheduled for IVIG therapy and saw that 38 had neither low antibody levels nor a recurrent infection, which is another indication for the treatment. The NP consulted 2 other employees about the issue, and the 3 of them canceled the IVIG therapy for the 38 patients.

Dr Fata's employees had internally challenged other practices they considered unethical, such as fabricating cancer diagnoses in patient records to justify insurance claims for chemotherapy and positron emission tomography (PET) scans. Dr Fata vehemently denies all the allegations.